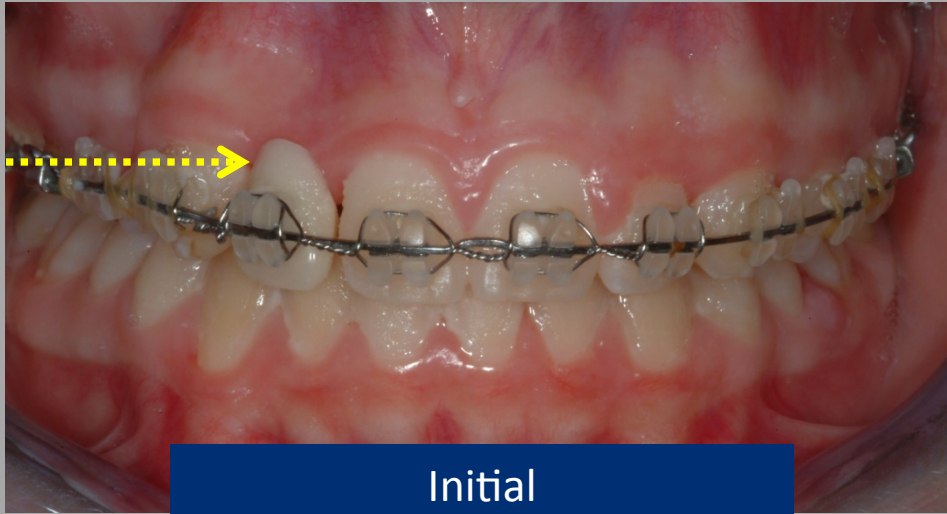


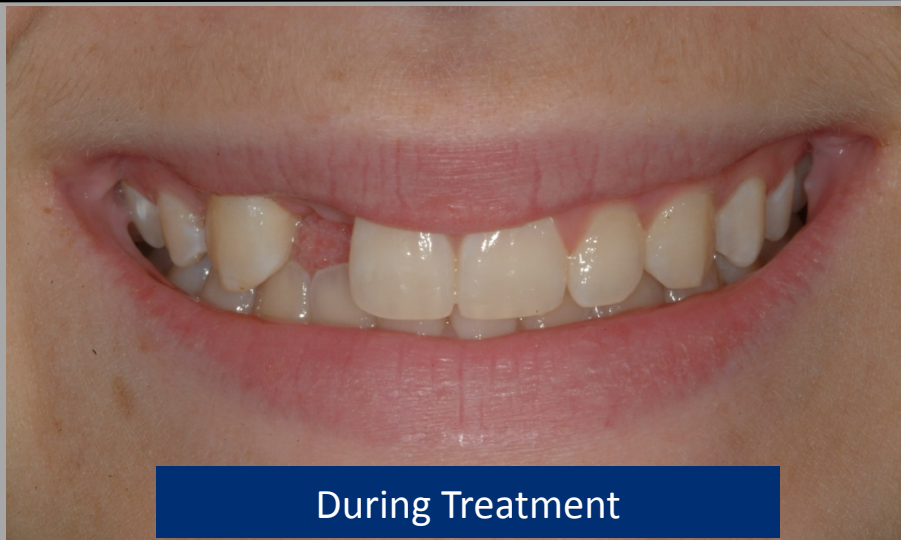Implant #7 with Crown

Background: HD was congenitally missing tooth #7 and required a dental implant #7.

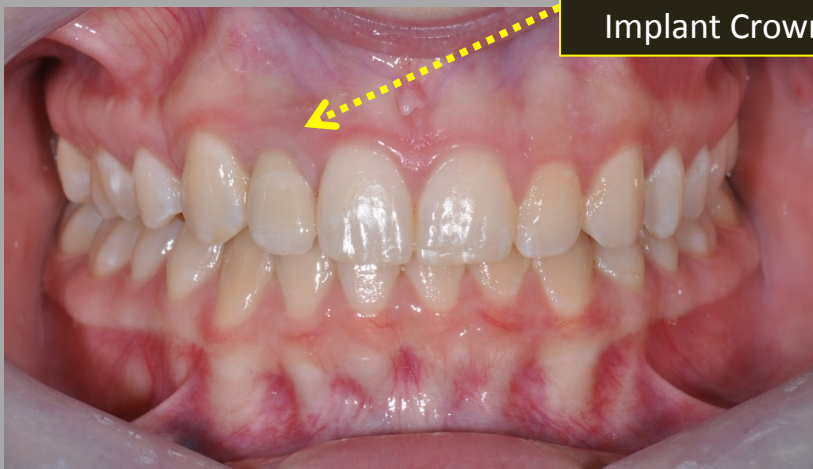
Fake tooth #7
attached to
her braces



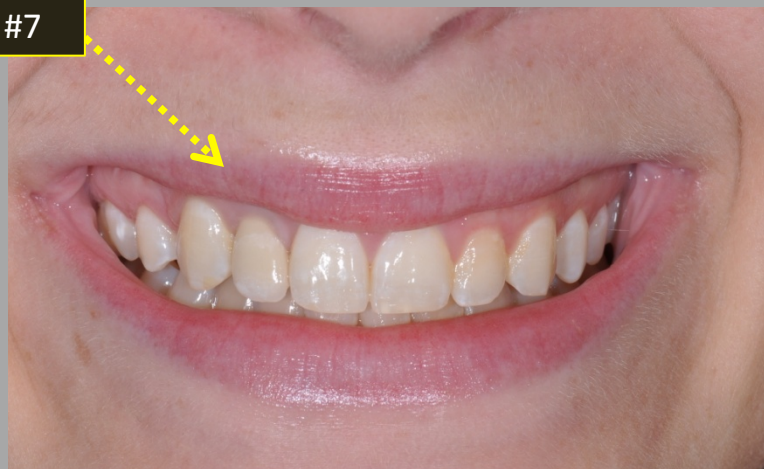
Initial



During Treatment



Implant Crown #7



Final Implant Crown #7

Testimonial: "I waited 18 years to have my tooth and Dr. Kubikian helped me every step of the way through the process and kept me relaxed the whole time from start to finish. I knew the outcome was going to be well worth it and it was!" H.D. - Ocean City, NJ