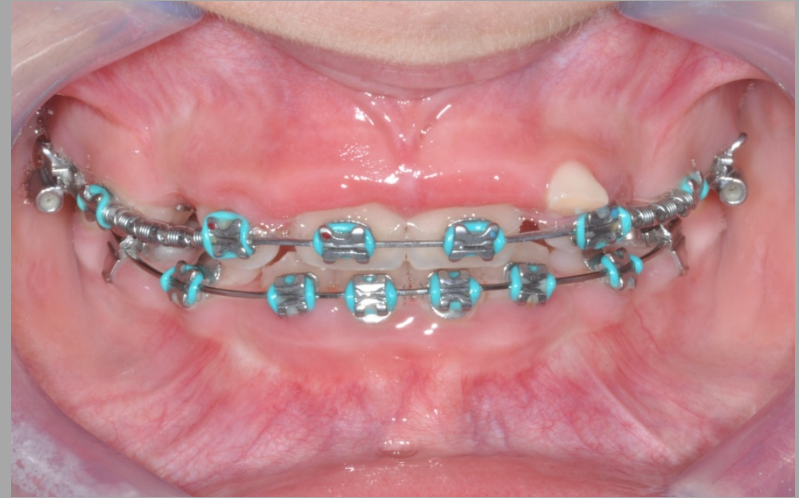
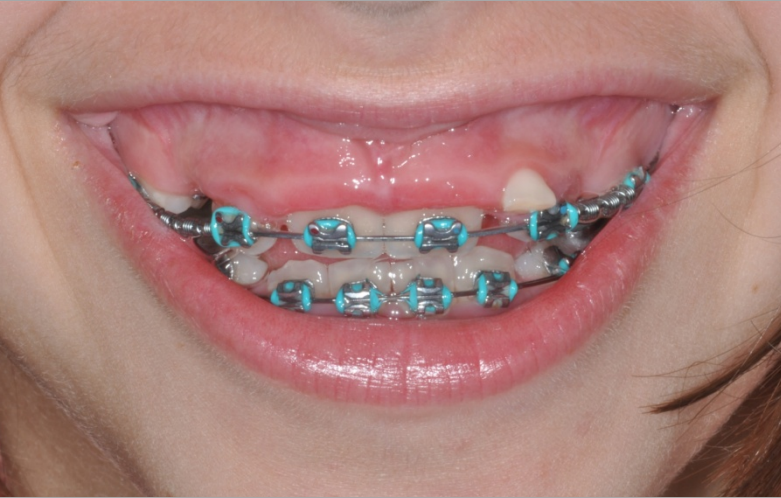
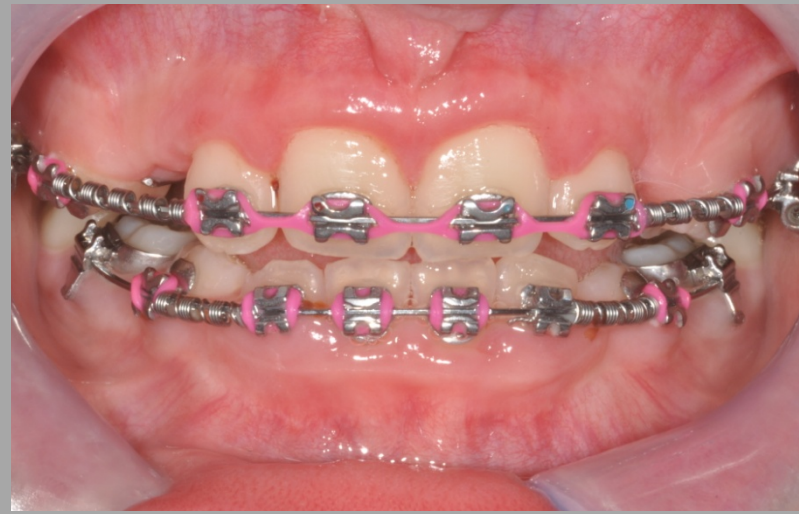
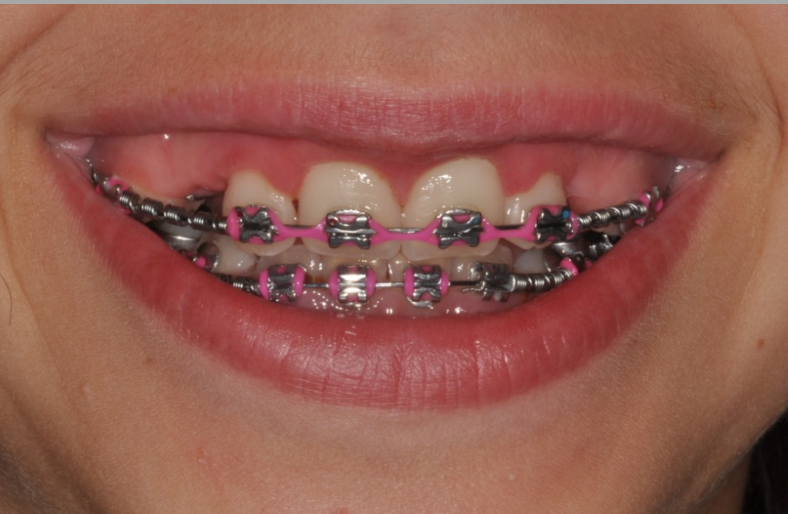Gingivectomy #7-10

Background: JL had gingival overgrowth with significant plaque accumulations during orthodontic therapy. Before the braces were removed, she had a gingivectomy performed to address these issues.



Thick overgrown gum tissue



Thinner, healthier gum tissue

Testimonial: “The procedure was totally painless. Dr. Kubikian was really nice. Now my teeth look so much better.” J.L. - Woolwich, NJ