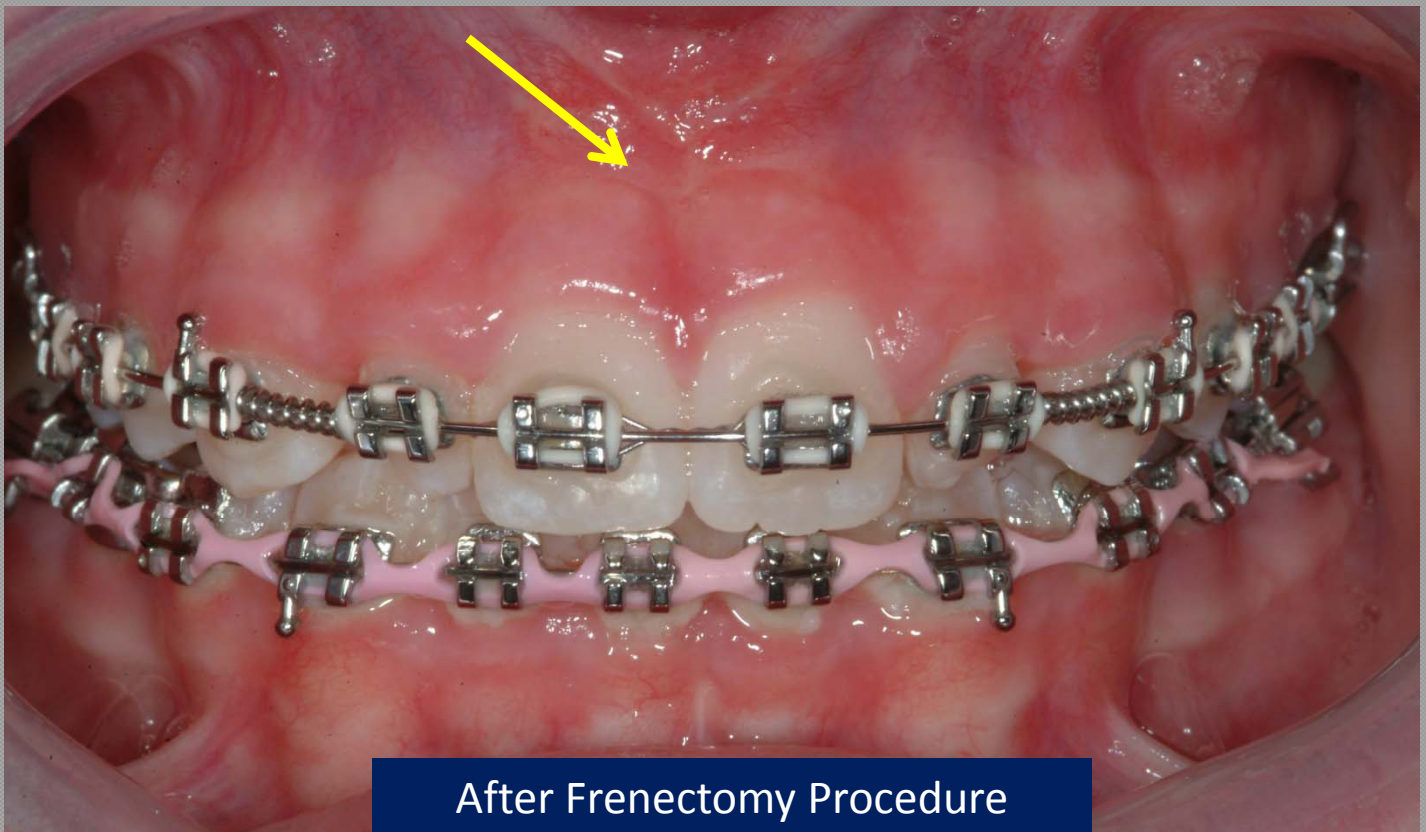
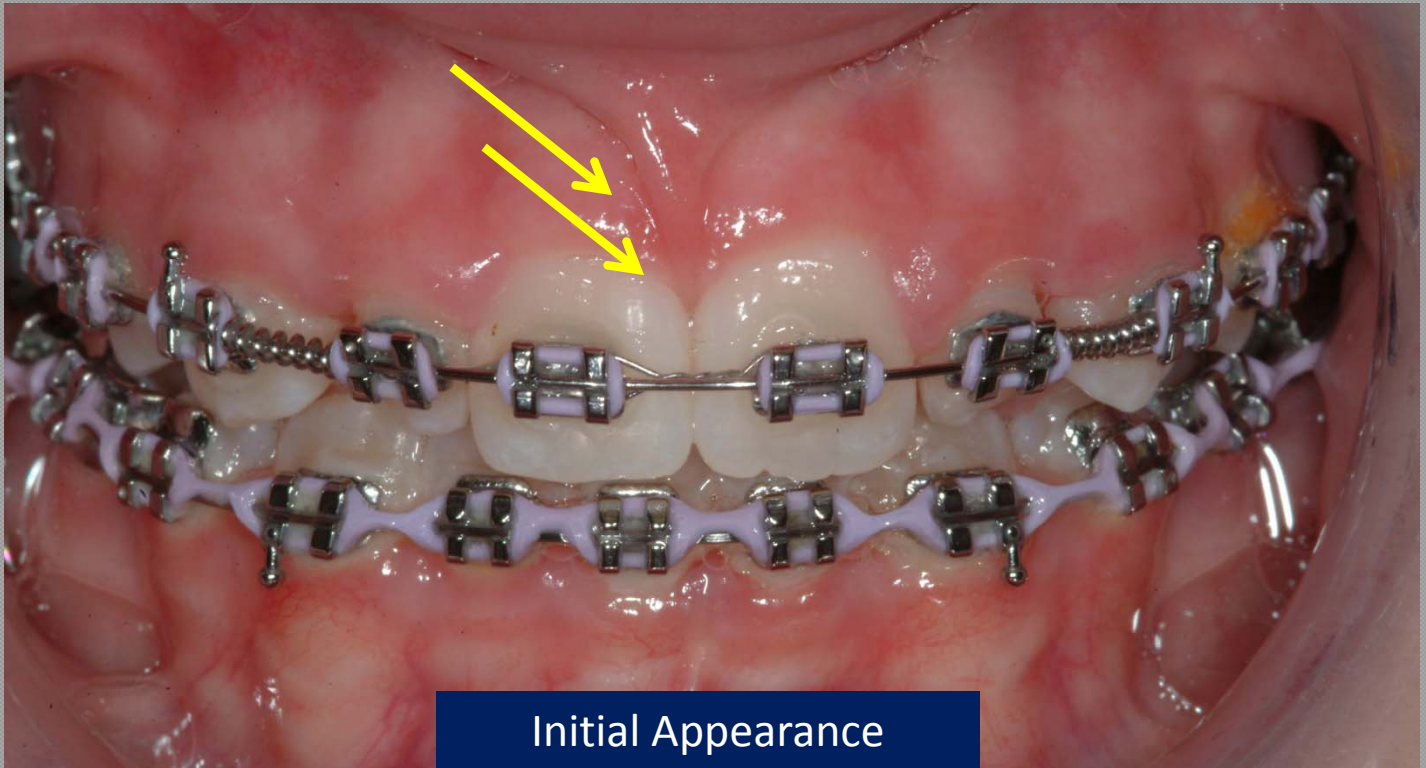


Freneotomy #8-9

Background: CM had a prominent frenum muscle between her top two teeth. In order to prevent an orthodontic relapse and possible recession, a freneotomy was performed.



Testimonial- "I was a little sore and all I needed was Motrin. Before, my muscle would reach my tooth and now it is easier to brush my teeth without causing soreness." -CM, Mullica Hill, NJ