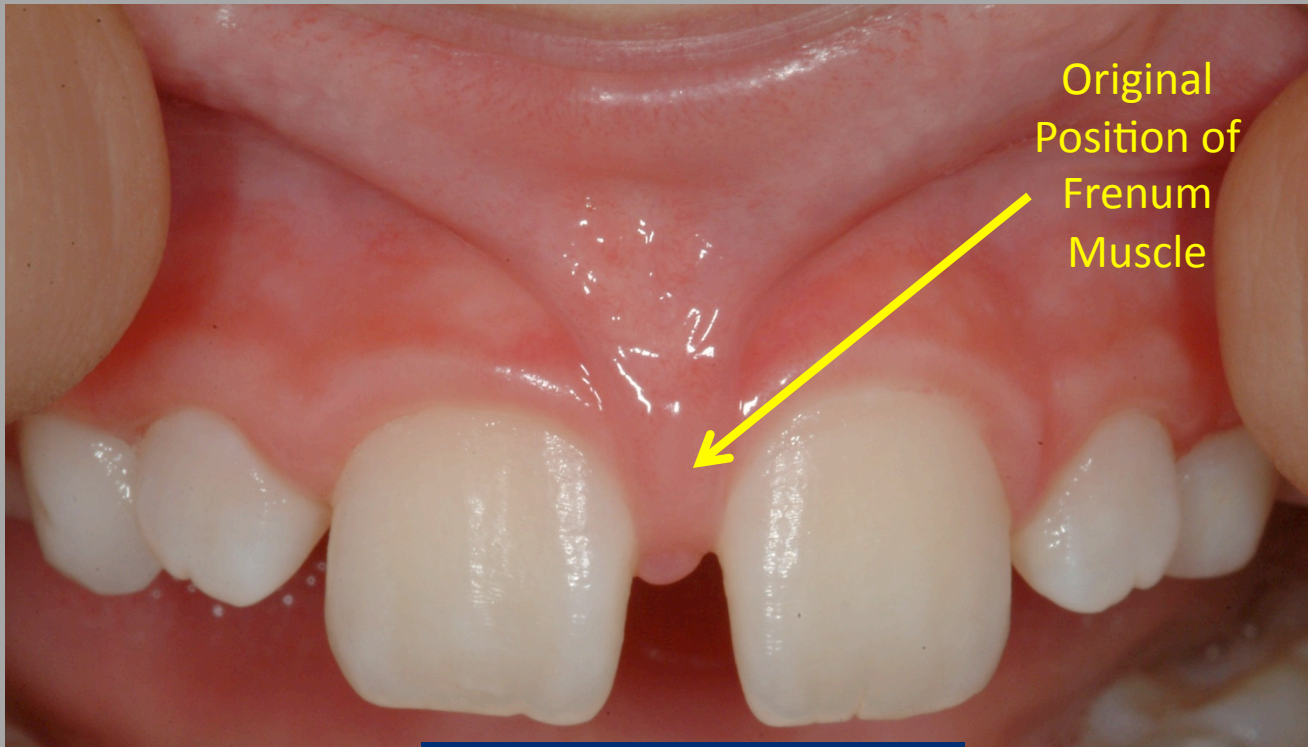
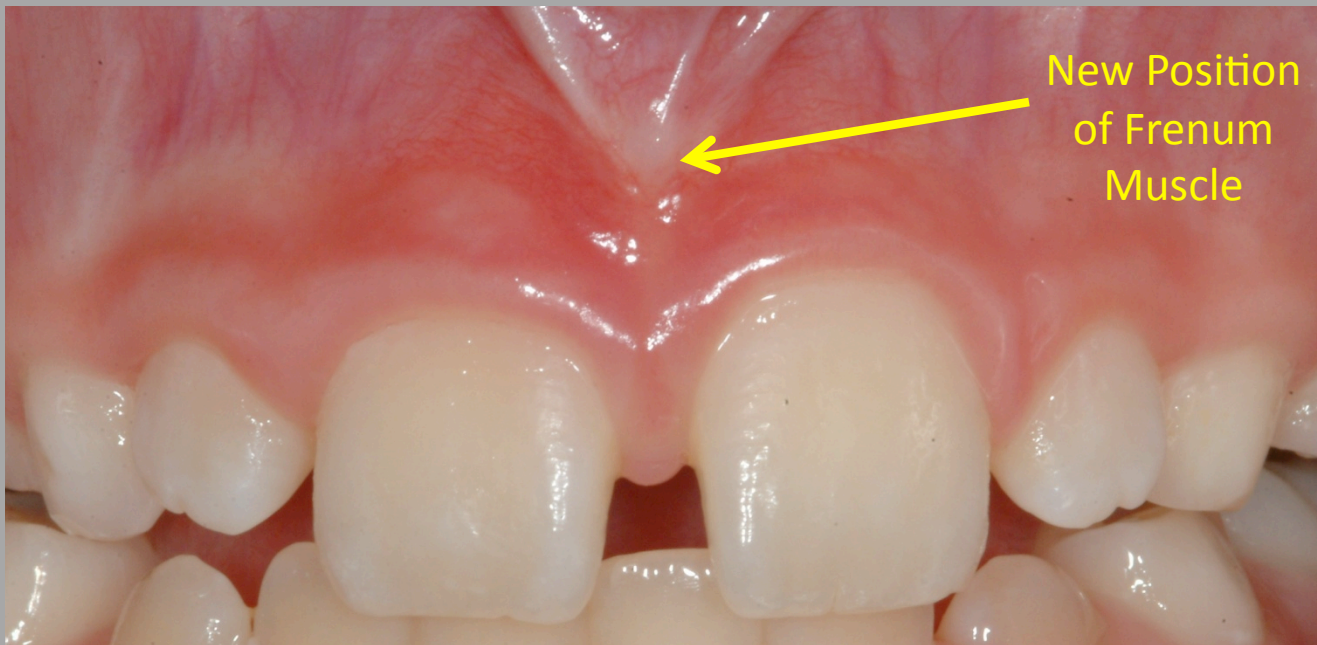

# Frenectomy #8-9

EB was unable to bite into foods with her front teeth because her frenum muscle was very prominent and would always get traumatized. She always had trouble brushing her teeth also.



Initial Appearance



After Frenectomy

*Testimonial: "I had trouble chewing and couldn't move my lip. But the frenectomy was easy and I'm so glad I had it done"*  
EB, 7 years old, West Deptford, NJ